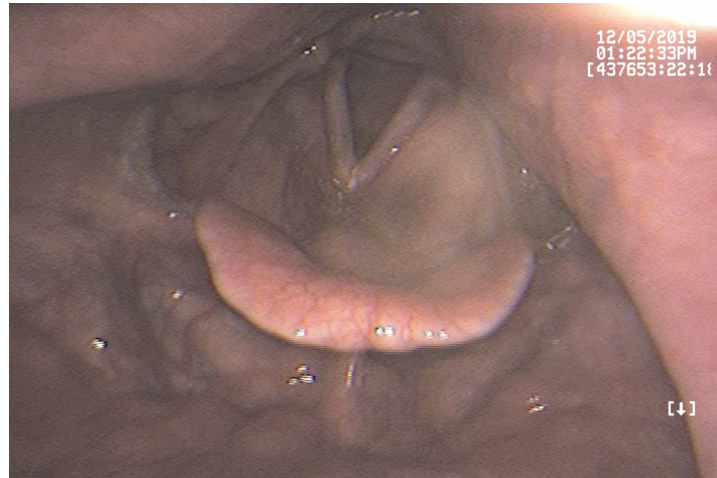


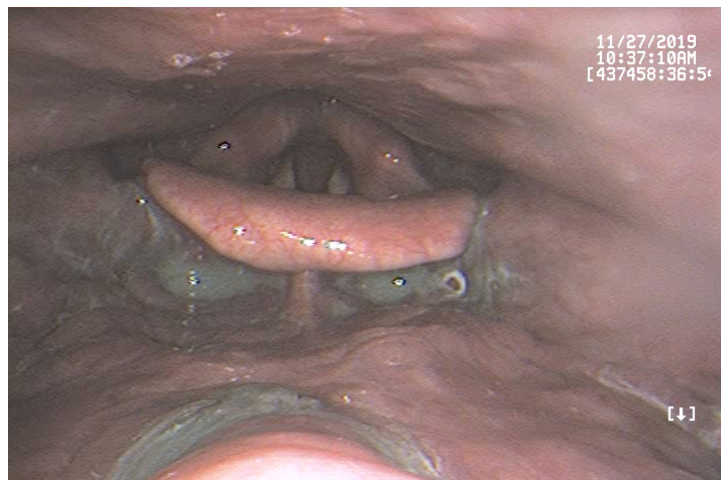
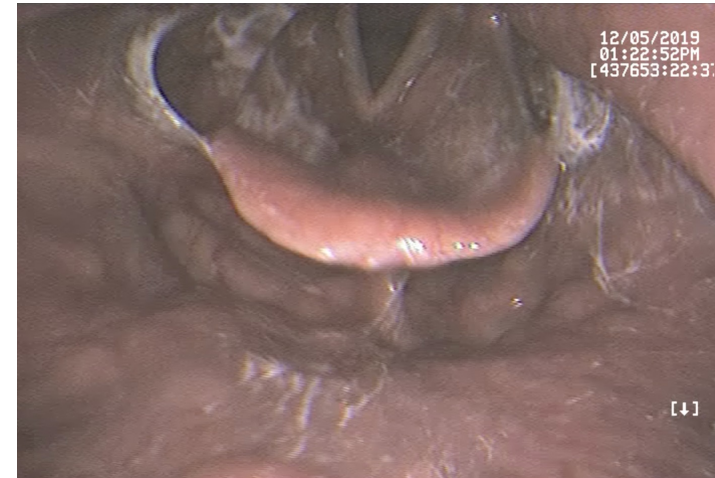
Supplemental Material S1. Endoscopic images that were provided to the raters for rating YPRSRS/BRACS and VASES ratings.

Valleculae (Yale); Oropharynx (VASES)

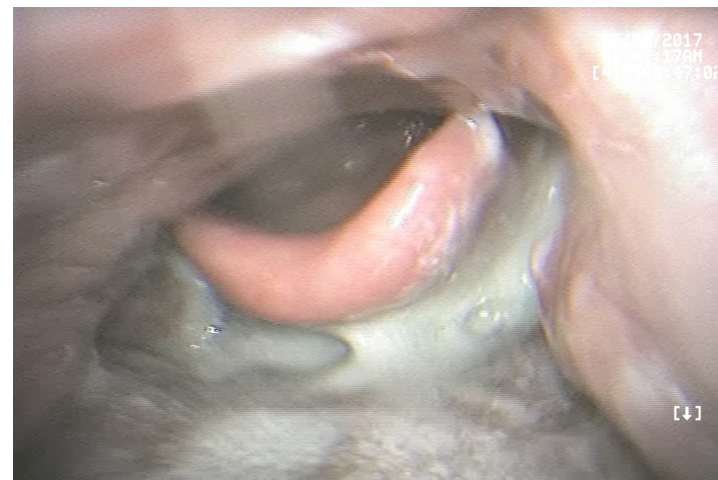
None



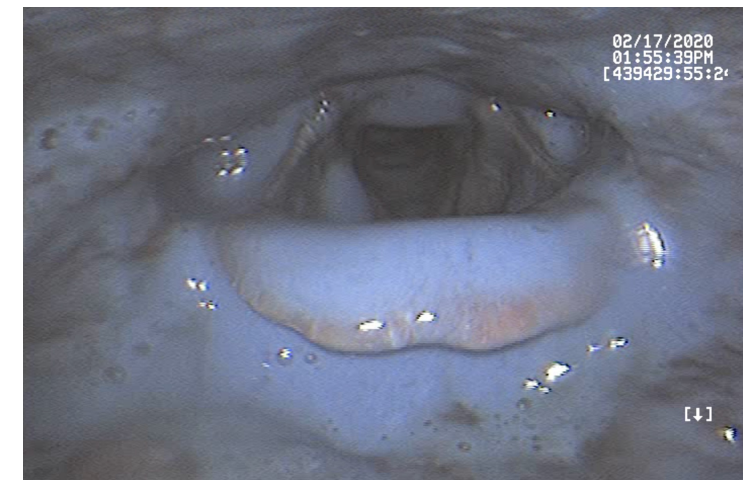
Trace



Mild



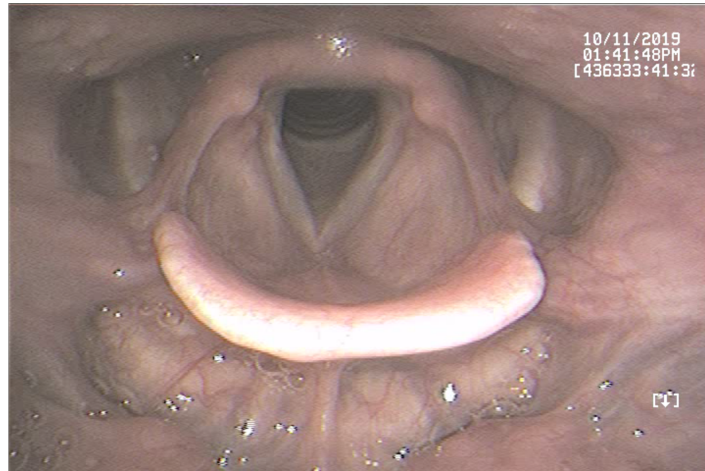
Moderate



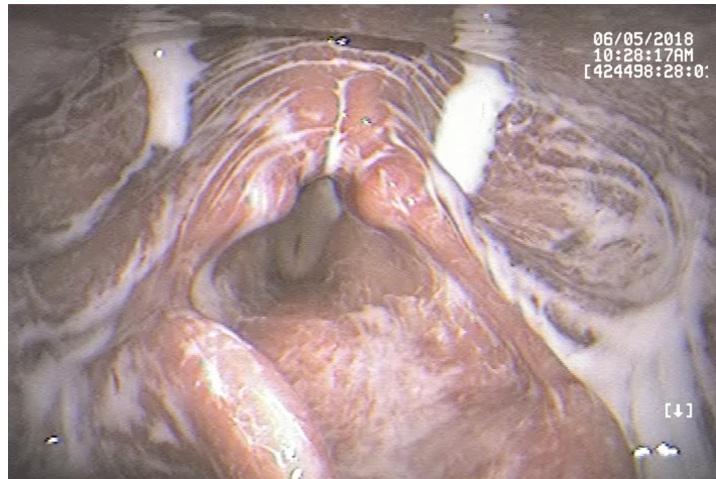
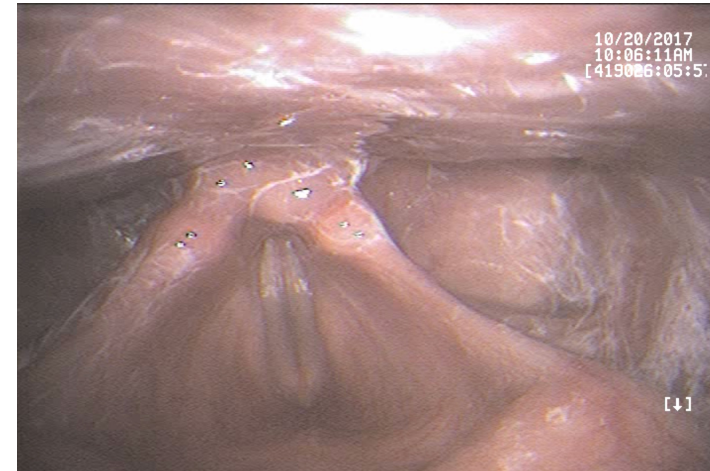
Severe

Piriforms (Yale); Hypopharynx (VASES)

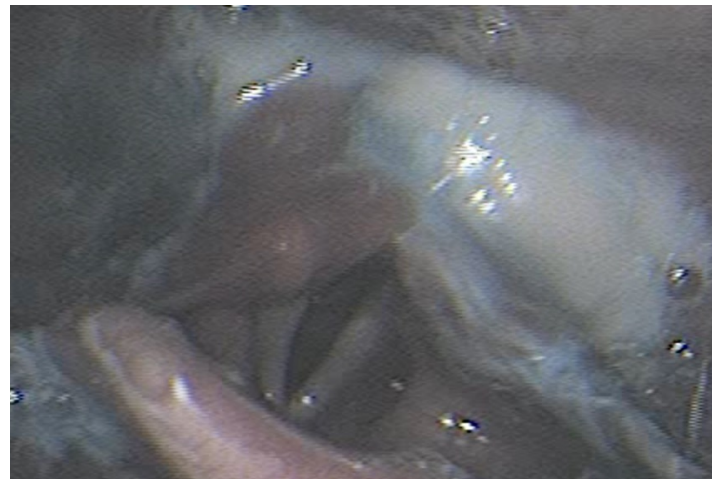
None



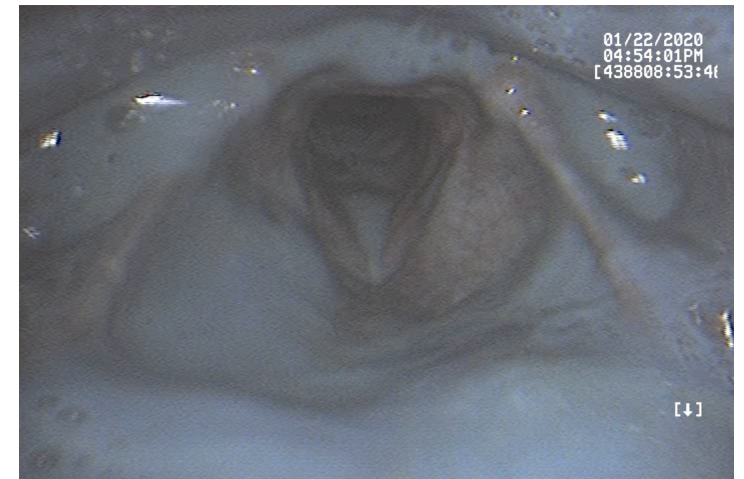
Trace



Mild



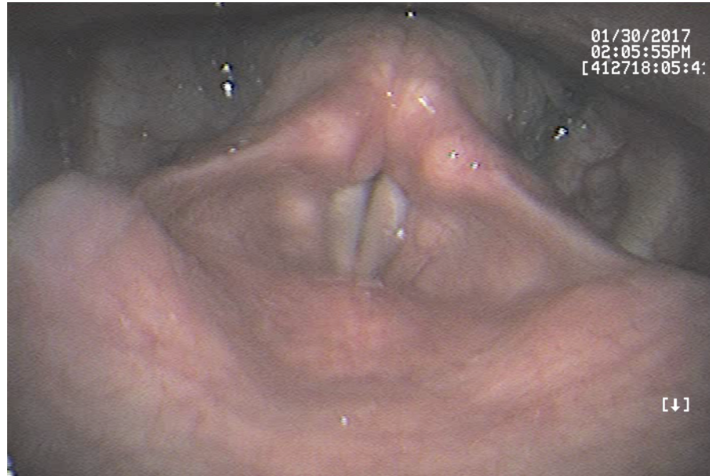
Moderate



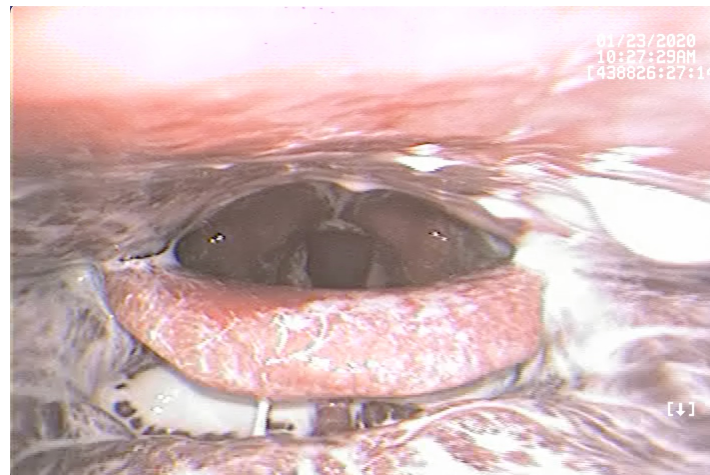
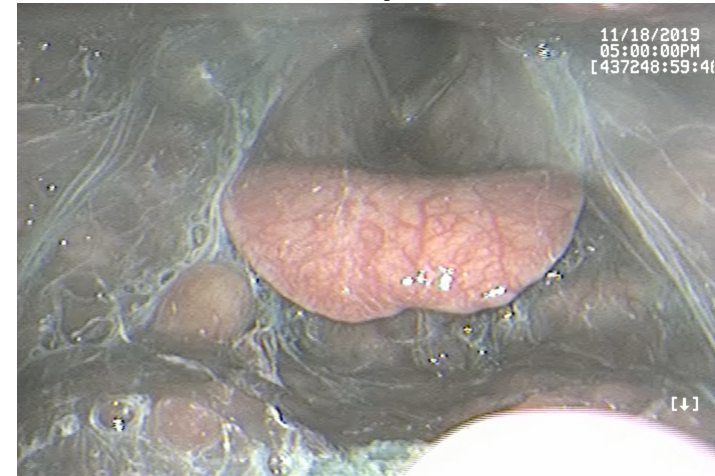
Severe

Epiglottitis (BRACS & VASES)

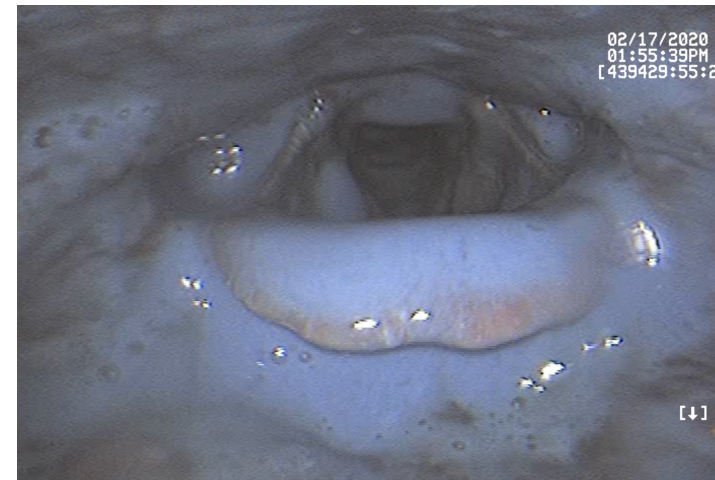
None



$< 1/3$



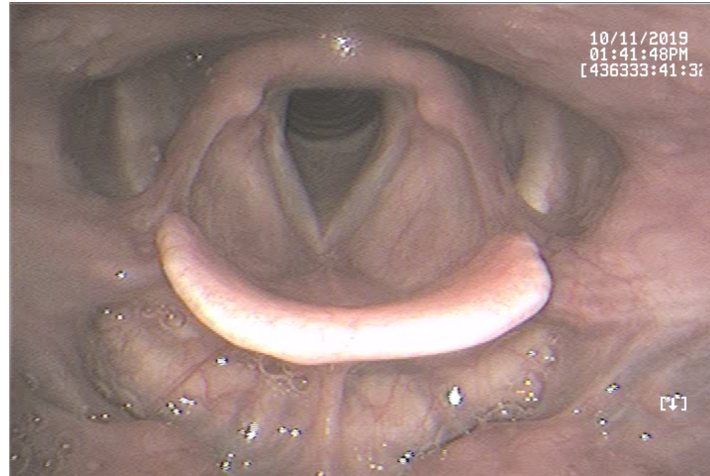
$1/3 - 2/3$



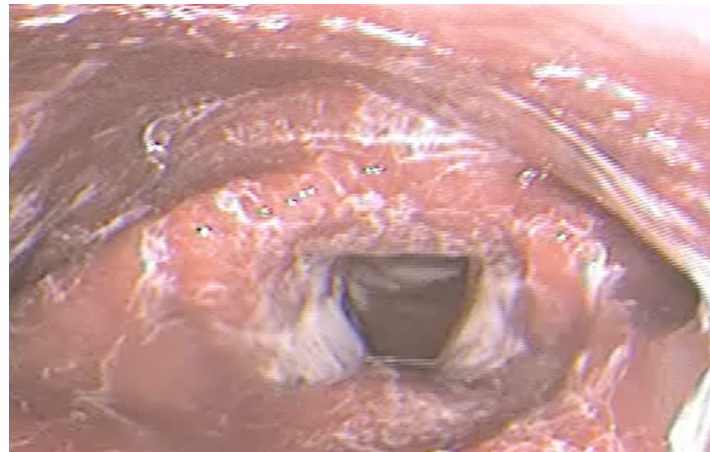
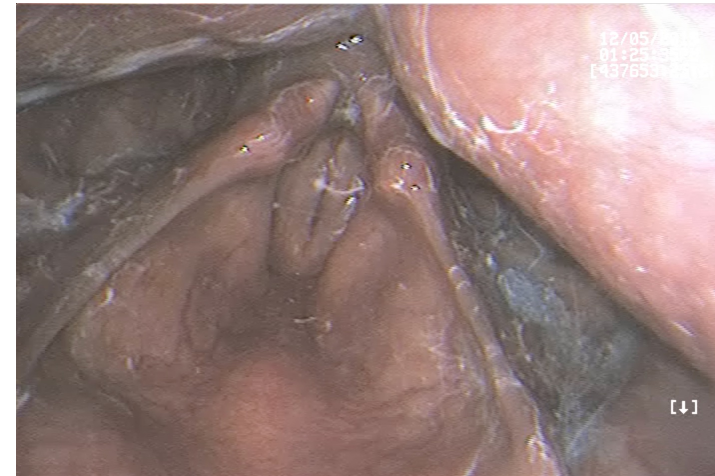
$> 2/3$

Laryngeal Vestibule (BRACS & VASES)

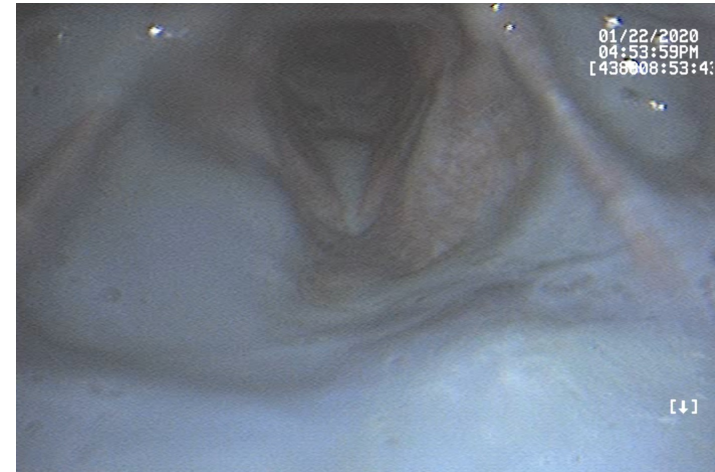
None



$< 1/3$



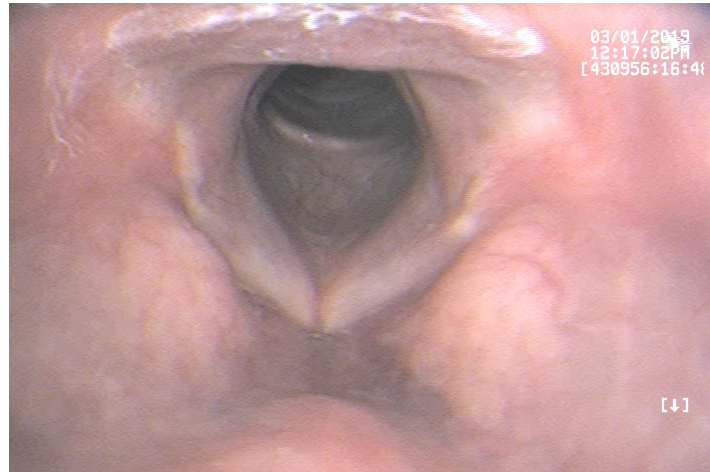
$1/3 - 2/3$



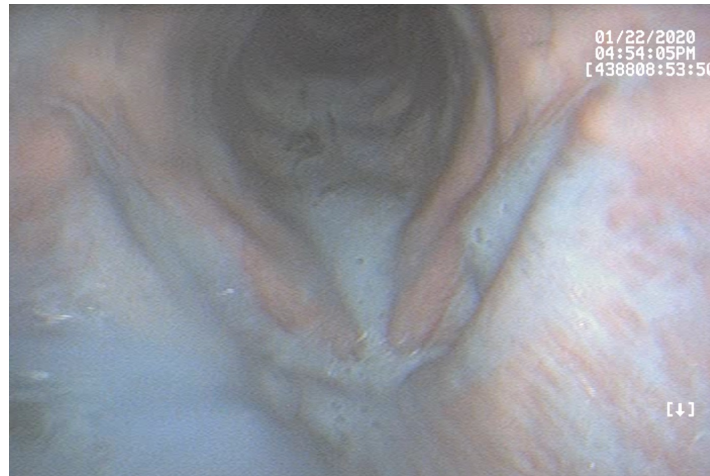
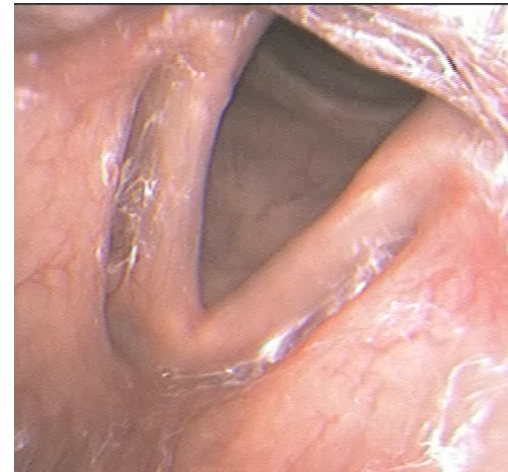
$> 2/3$

Vocal Folds (BRACS & VASES)

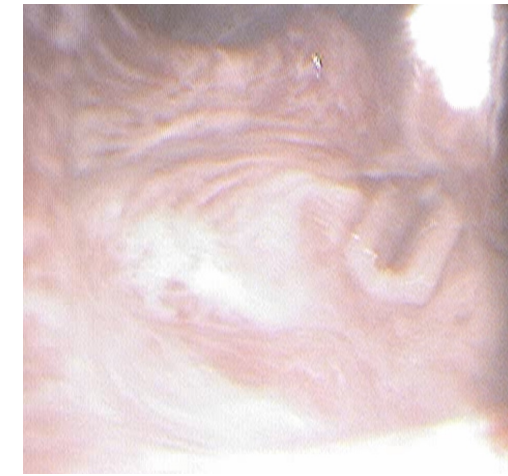
None



$< 1/3$



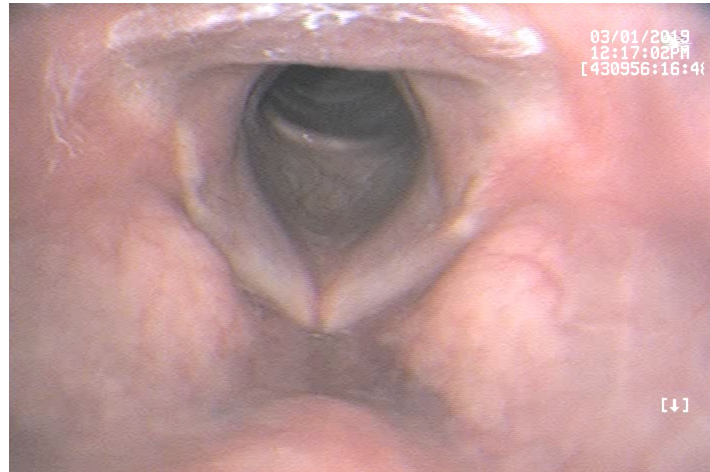
$1/3 - 2/3$



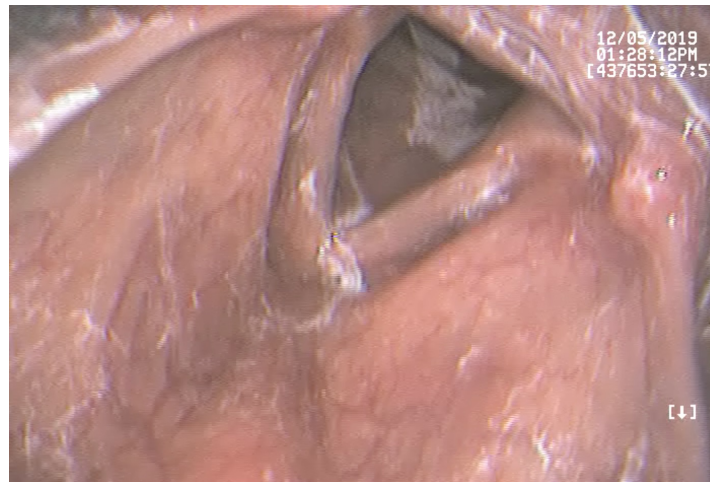
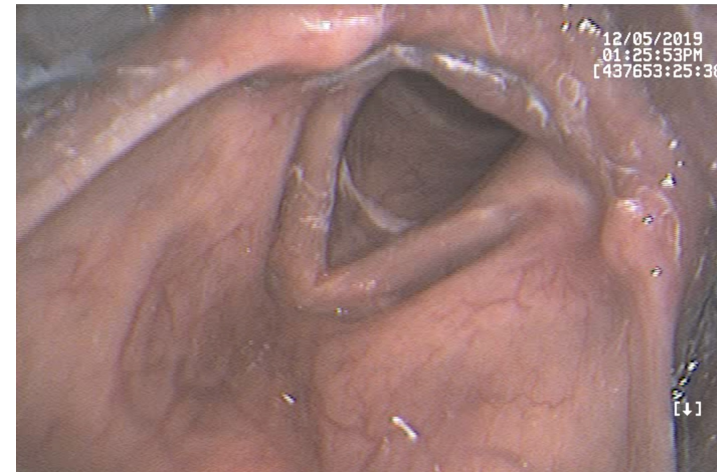
$> 2/3$

Subglottis (BRACS & VASES)

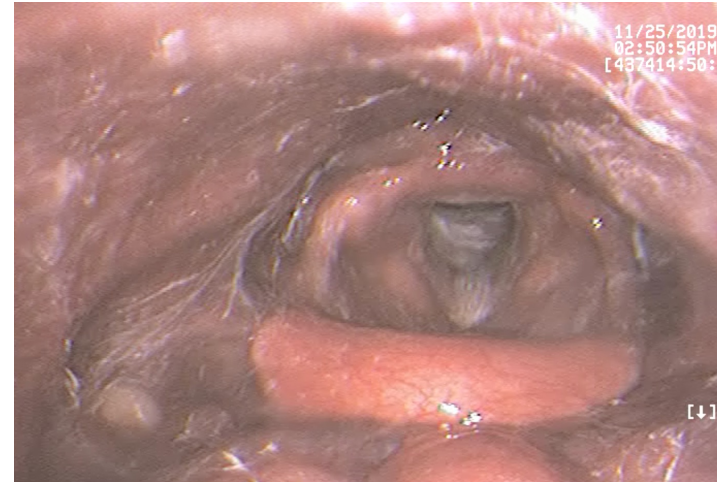
None



$< 1/3$



$1/3 - 2/3$



$> 2/3$